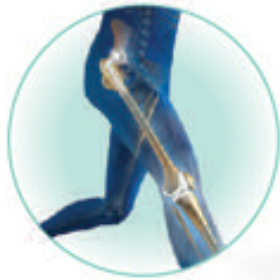

SIMULATED CBD- HIP & KNEE

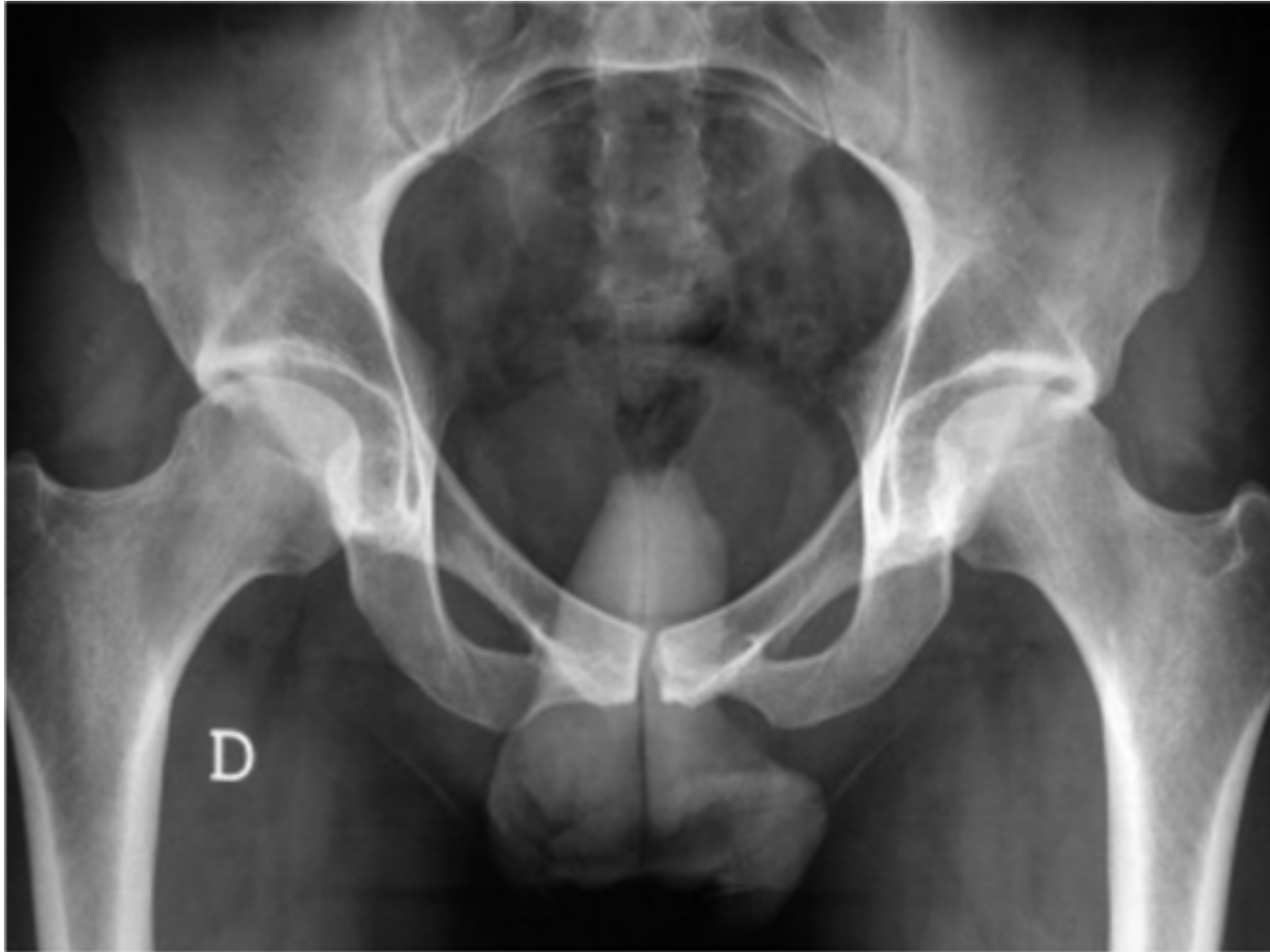

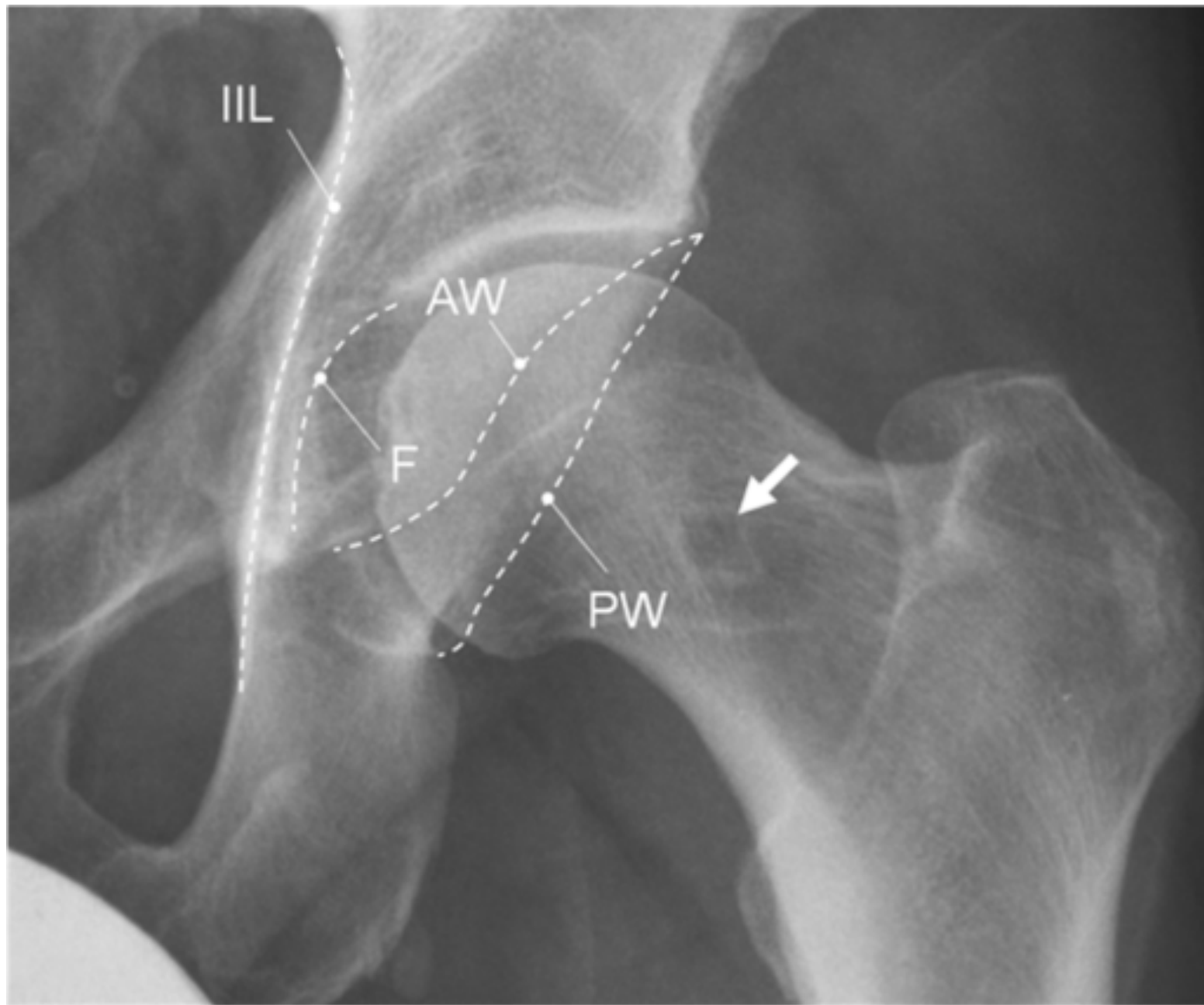
Mr. Satish Kutty MB BS, FRCS I, MSc, FRCS (Tr & ORTH)

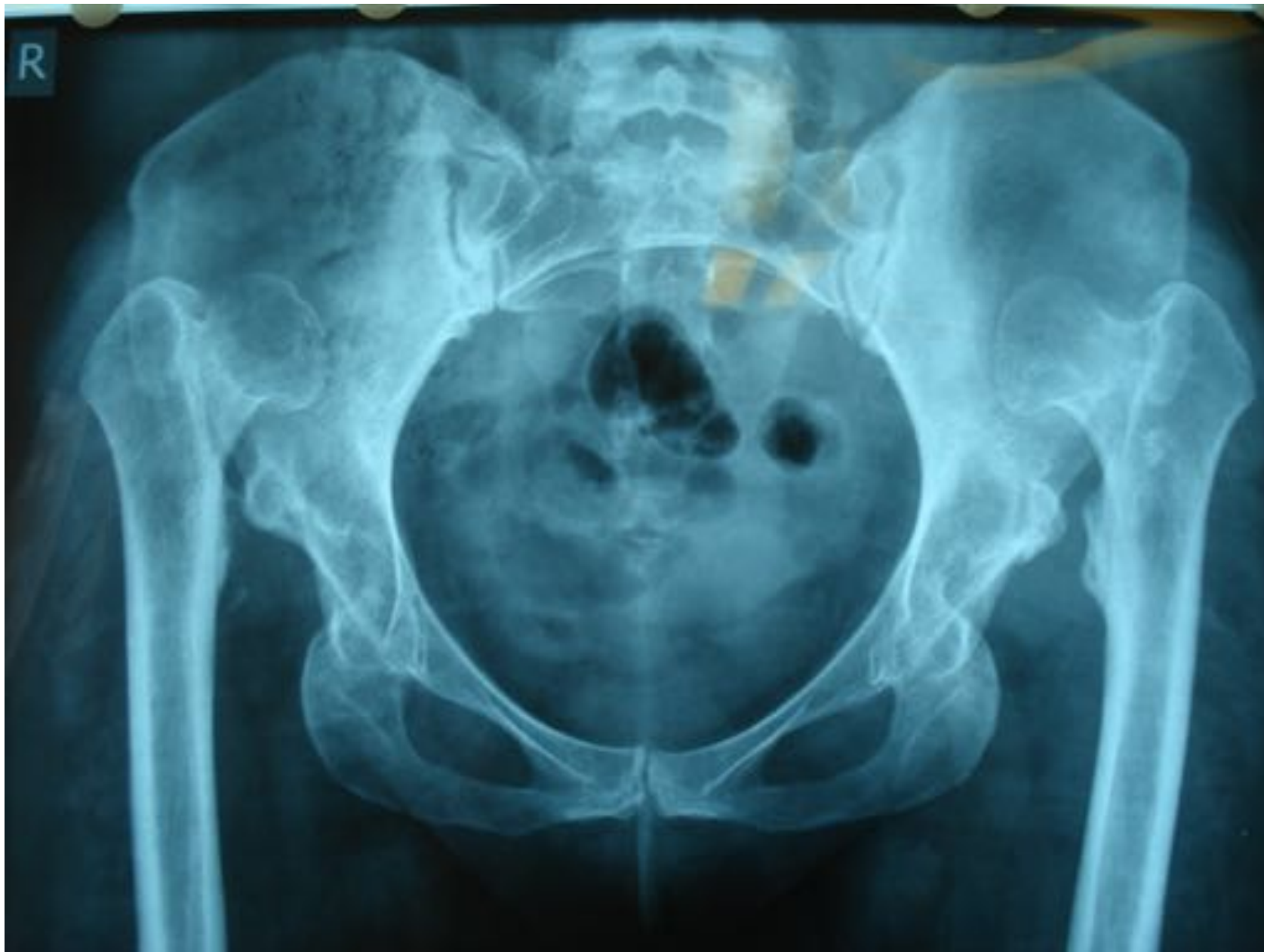Consultant Orthopaedic Surgeon

Honorary Clinical Senior Lecturer **Surgical tutor**

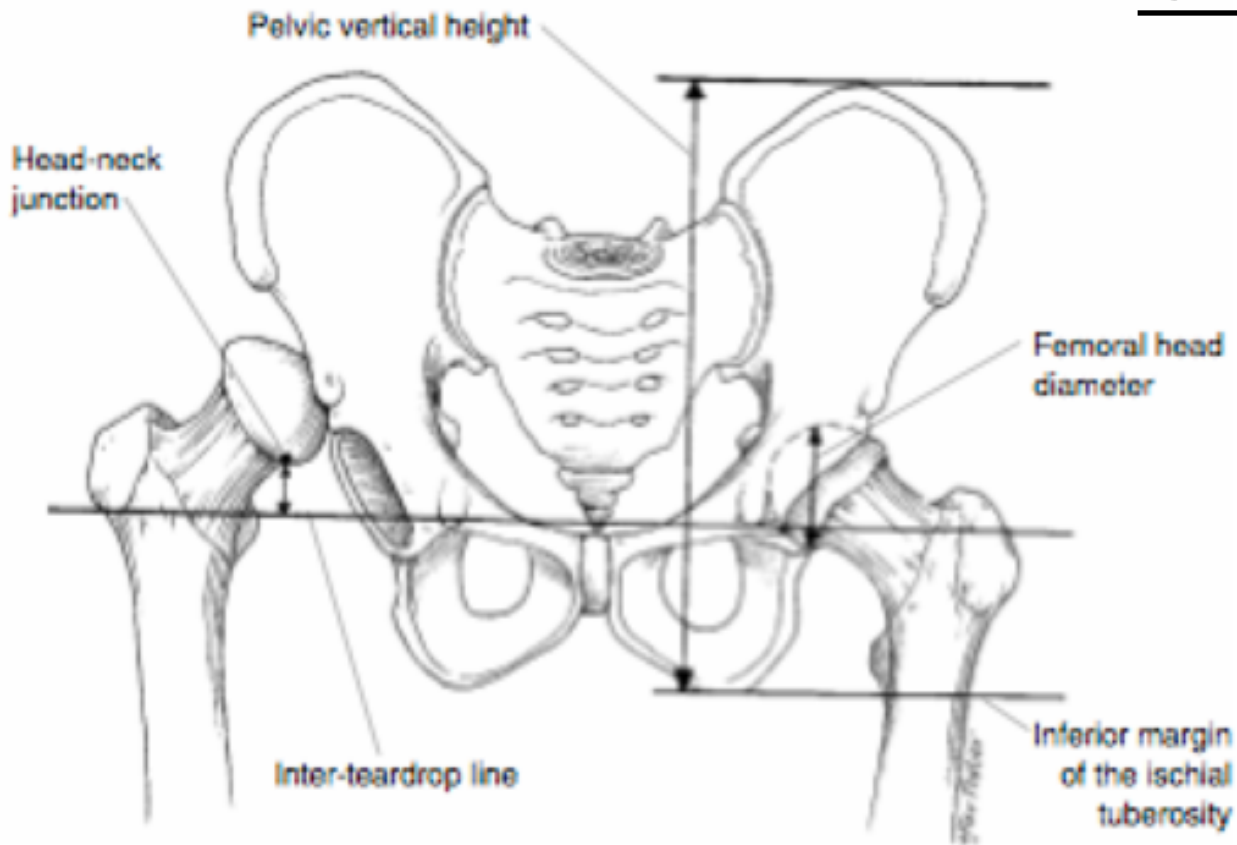
The Princess Alexandra Hospital **NHS**
NHS Trust







Crowe classification

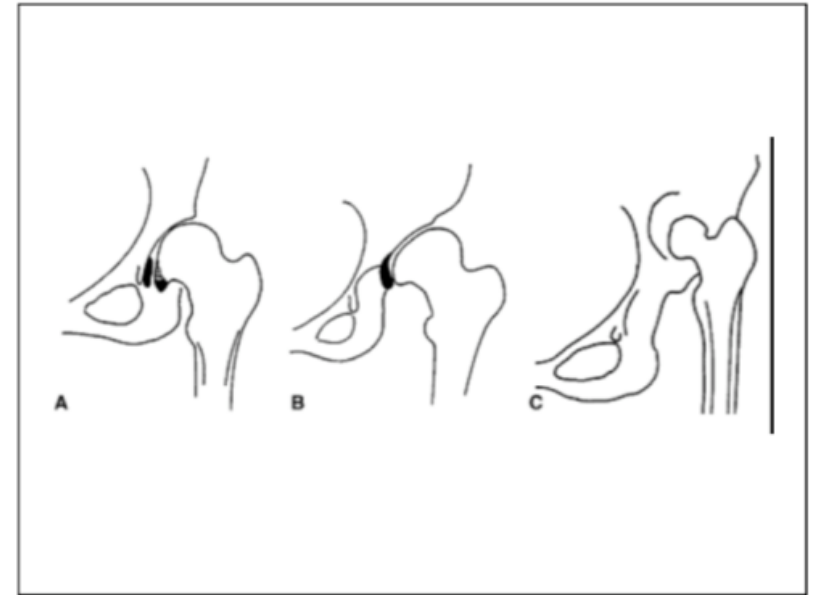


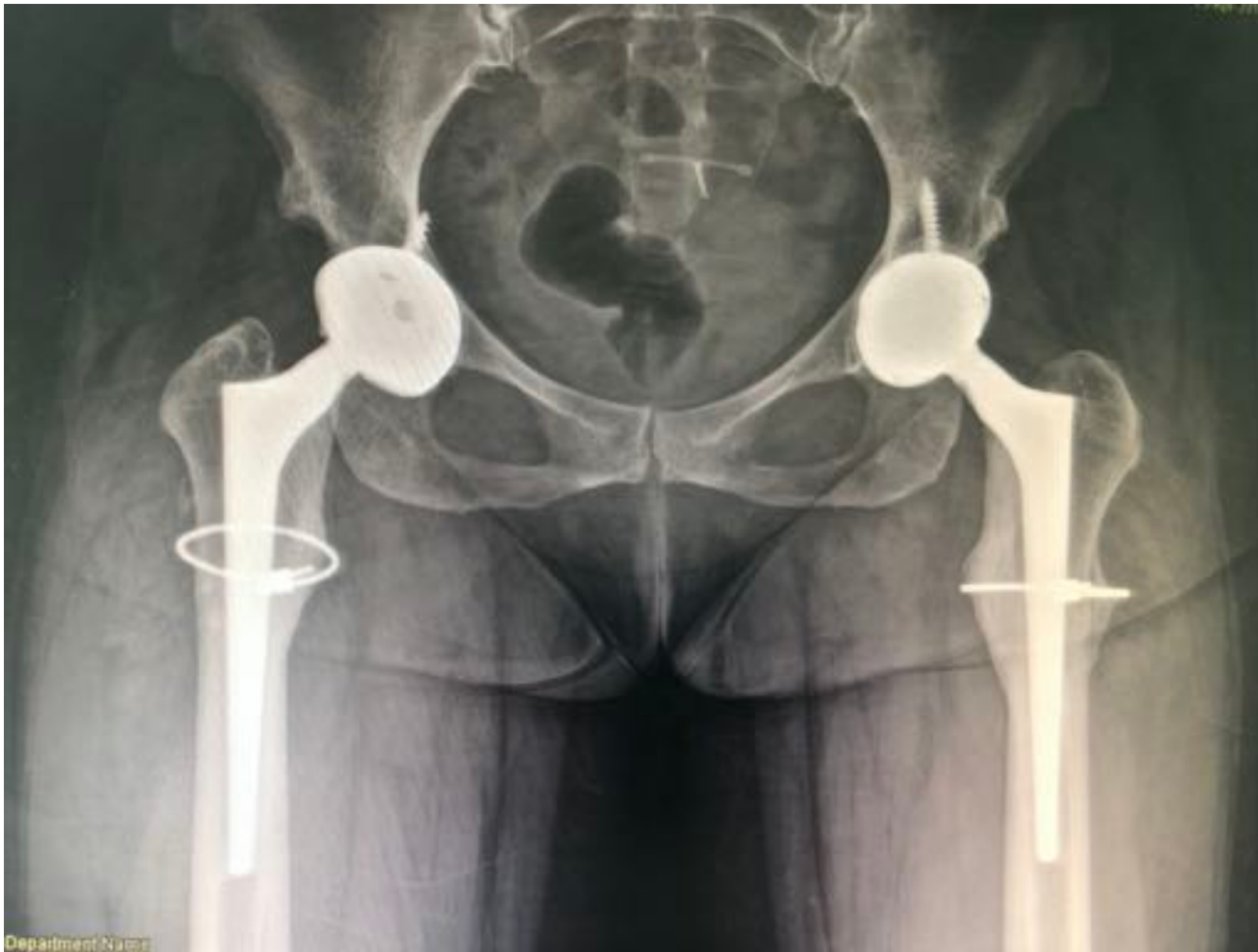Measurement of proximal migration from the inter-tear drop line

Crowe I	Proximal subluxation of <50% of the height of the femoral head
Crowe II	50-75% subluxation
Crowe III	75-100% subluxation

Hartofilakidis classification

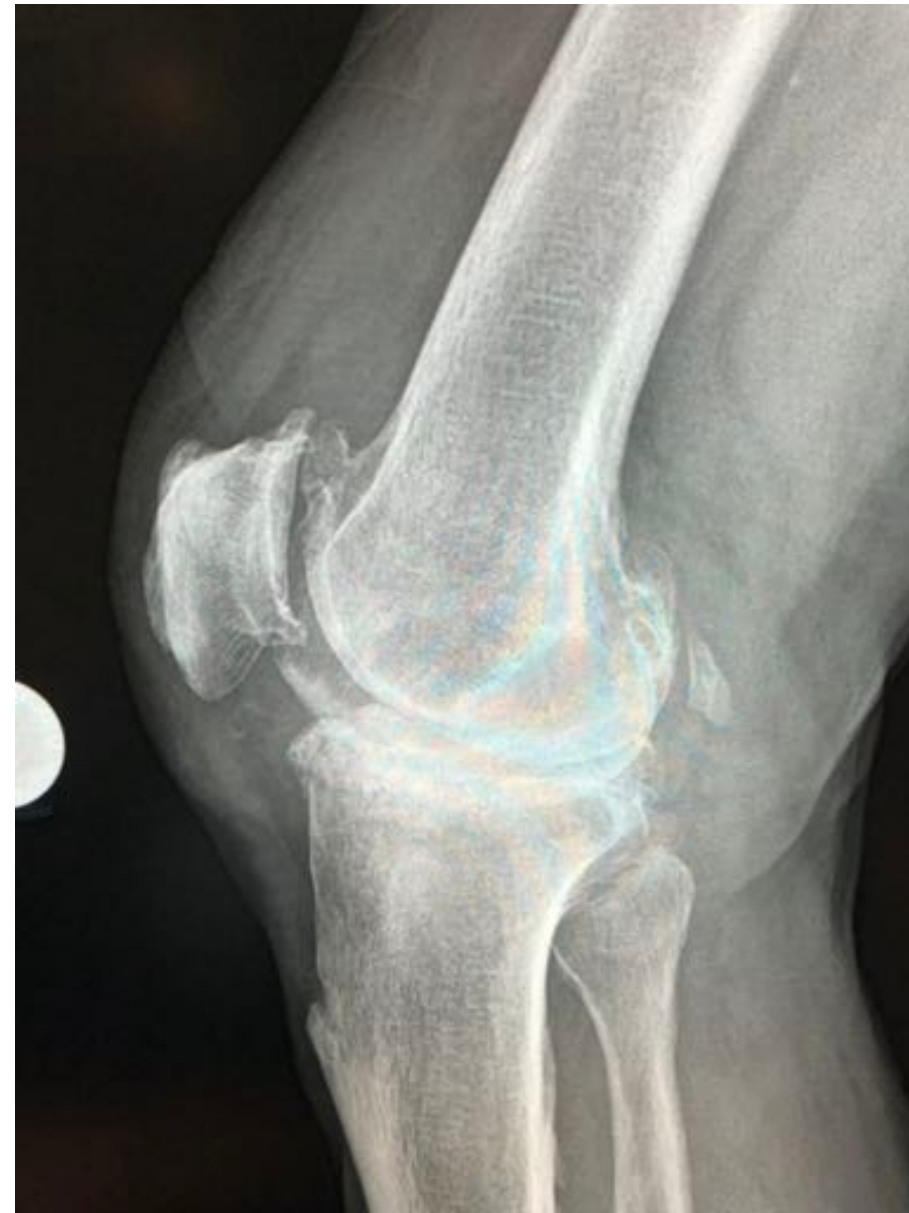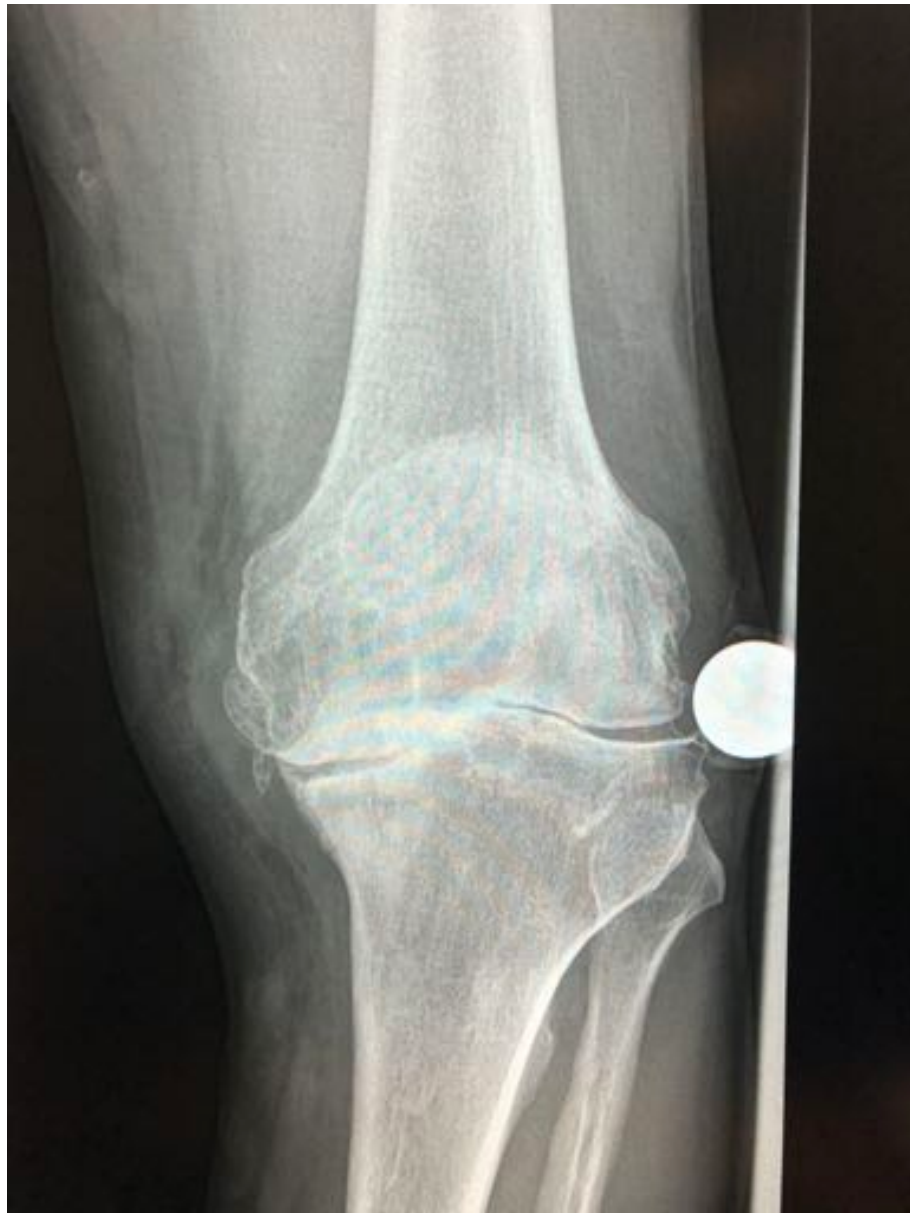- **Dysplasia** – Femoral head subluxated but still contained in the original acetabulum
- **Low** – Femoral head articulates with the false acetabulum that partially overlaps the true acetabulum
- **High** – Femoral head articulates with a hollow in the acetabular wing

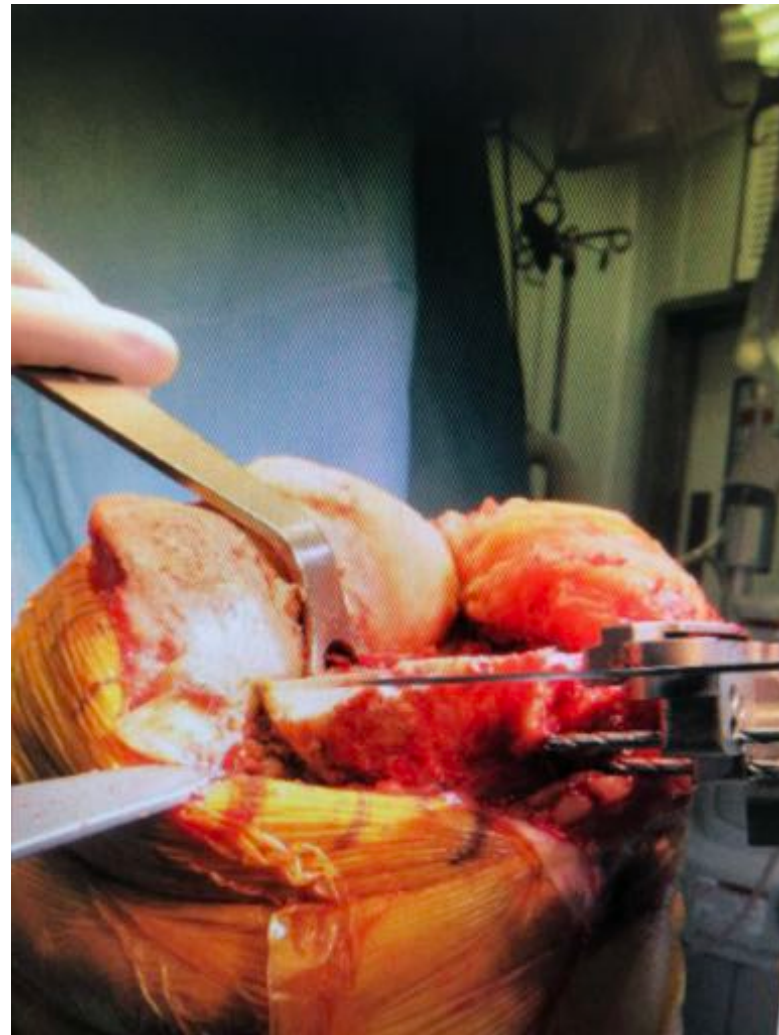
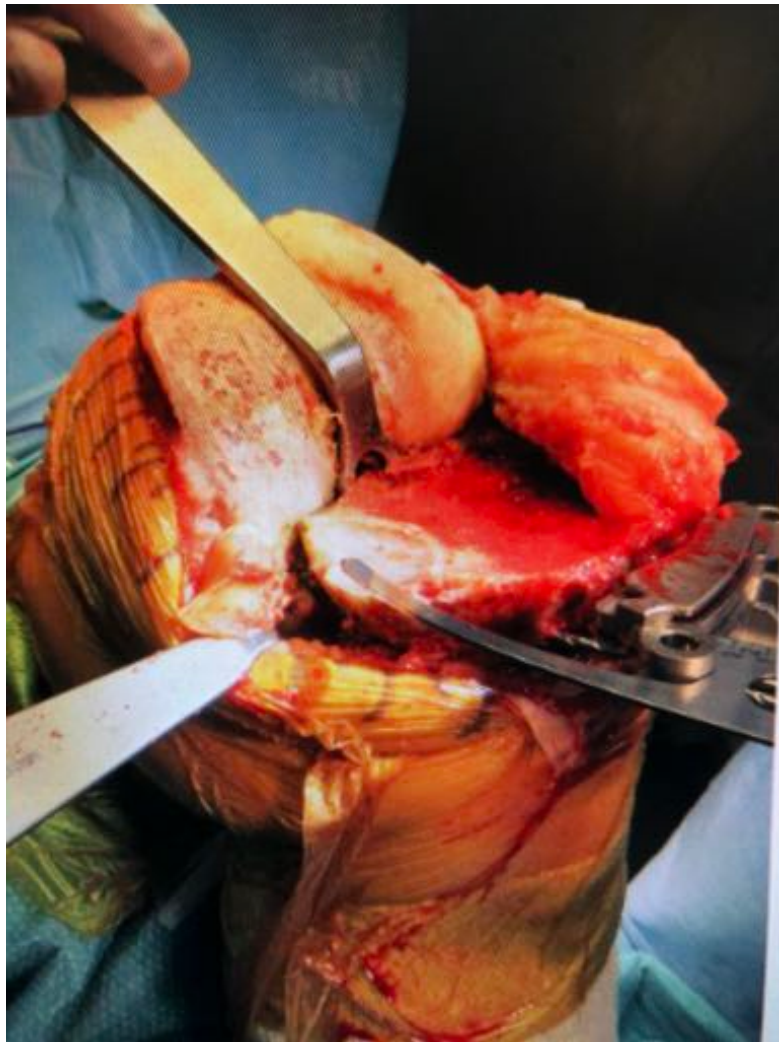
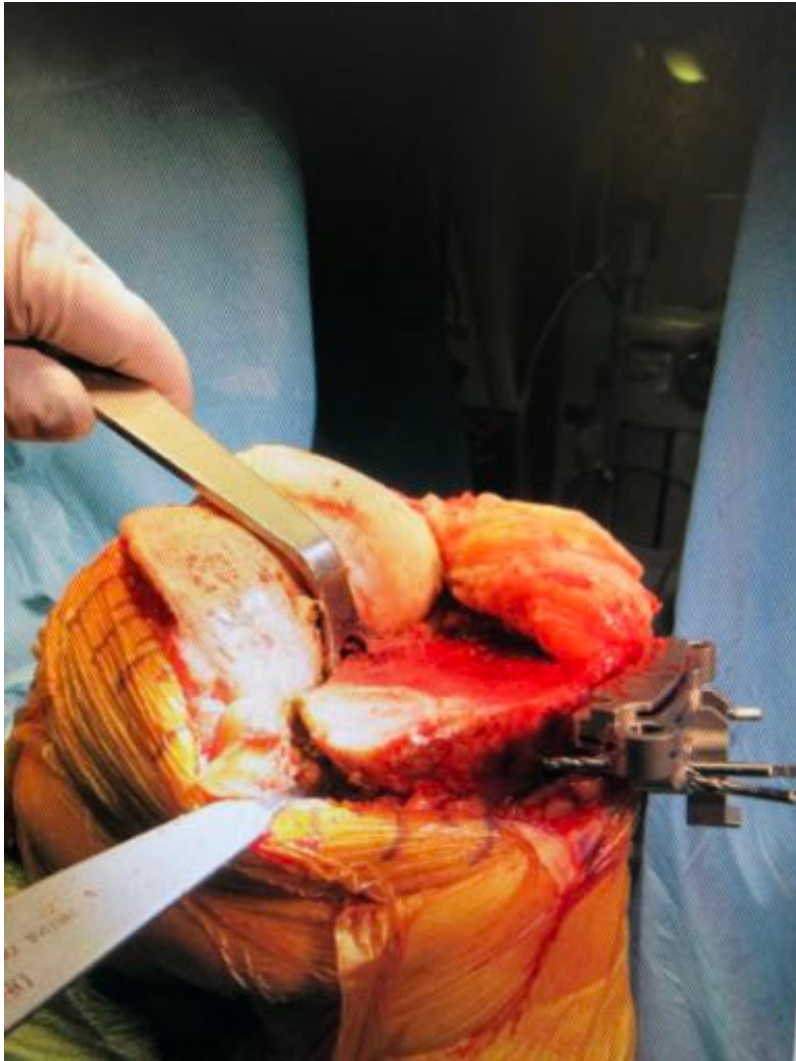

Department Name







The Princess Alexandra Hospital
NHS Trust



